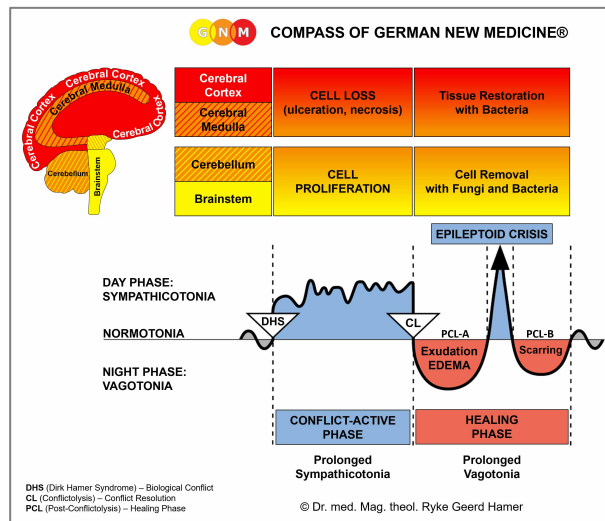




BIOLOGICAL SPECIAL PROGRAMS

EYES

written by Caroline Markolin, Ph.D.



Tear Glands

Tear Ducts

Eyelid Glands

Eyelid Gland Ducts

Eyelid Skin

Eyelid Muscles

Conjunctiva – Cornea – Lens

Choroid – Ciliary Body – Iris

Pupil Muscles

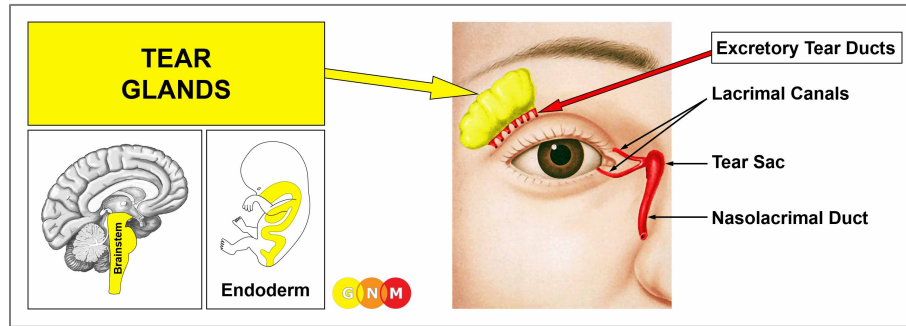
Ciliary Muscles

Extraocular Muscles

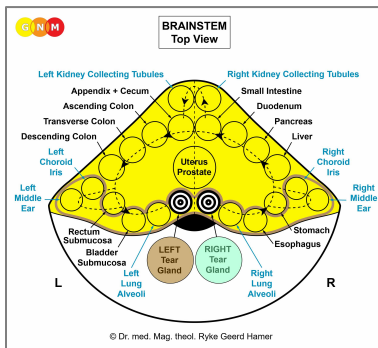
Retina

Vitreous Body

Rev. 1.10



DEVELOPMENT AND FUNCTION OF THE TEAR GLANDS: The tear glands are located in the temporal orbit (eye socket) on the outer portion of the upper eyelids. They produce the watery layer of the tear film that keeps the outer part of the eye and the conjunctiva moist. The tear fluid reaches the eye through the excretory tear ducts. Excess tears drain through the lacrimal canals, tear sac, and nasolacrimal duct into the nasal cavity. In evolutionary terms, the tear glands developed from the intestinal mucosa of the original gullet. Like the intestinal cells that digest the “food morsel”, the biological function of the tear glands is to “digest” (secretory quality) the “visual morsel”. The tear glands consist of intestinal cylinder epithelium, originate from the endoderm and are therefore controlled from the brainstem.



BRAIN LEVEL: In the **brainstem**, the tear glands have two control centers that are orderly positioned within the ring form of the brain relays that control the organs of the alimentary canal.

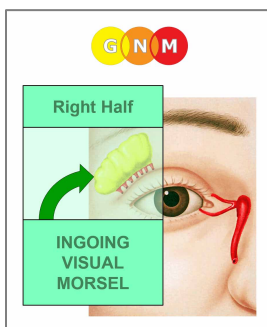
The right tear gland is controlled from the right side of the brainstem; the left tear gland is controlled from the left brainstem hemisphere. There is no cross-over correlation from the brain to the organ.

NOTE: The mouth and pharynx, tear glands, Eustachian tubes, thyroid gland, parathyroid glands, pituitary gland, pineal gland, and choroid plexus share the same brain relays.

BIOLOGICAL CONFLICT: The biological conflict linked to the tear glands is a “**morsel conflict**”, specifically, a conflict related to a “**visual morsel**” (see also choroid, iris, and ciliary body).

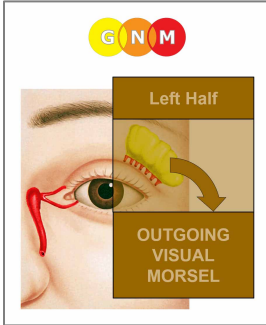
In line with evolutionary reasoning, **morsel conflicts** are the primary conflict theme associated with **brainstem-controlled organs** deriving from the endoderm.

RIGHT TEAR GLAND



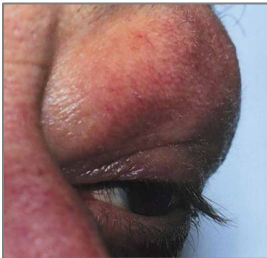
Equivalent to the right half of the mouth and pharynx, the **right tear gland** correlates to an “**ingoing morsel**” and to “**not being able to catch a visual morsel**” because the morsel was ignored by someone else. For example: A child has set eyes on a toy and expects to get it but the parents ignore it, hence, it could not grab the “visual morsel”; a child wants to see his friends or wants to watch TV but the parents don’t allow it; a woman draws her husband’s attention to a ring in a window of a jewelry shop and anticipates getting the ring, but he disregards the “visual morsel” she desires.

LEFT TEAR GLAND

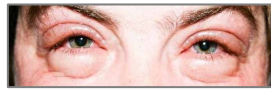

Equivalent to the left half of the mouth and pharynx, the **left tear gland** relates to an “**outgoing morsel**” and to “**not being able to eliminate a visual morsel**” **because the morsel was ignored by someone else**. For example: A painter wants to sell his paintings but no one takes notice of them; a real estate agent is unable to sell a property, a salesman is left with his products; a person wants to get rid of “morsels” at a garage sale but no one shows up; due to a cancellation a lecturer is unable to share his presentation; a child shows its mother a drawing but she pays no attention.

CONFLICT-ACTIVE PHASE: Starting with the DHS, during the conflict-active phase cells in the tear gland proliferate causing an **enlargement of the lacrimal gland**. The **biological purpose of the cell increase** is to enhance the production of tear fluid so that the “visual morsel” can be better absorbed (right tear gland) or expelled (left tear gland). Thus, the affected **eye is teary and watering** (see also nasolacrimal ducts and conjunctiva).



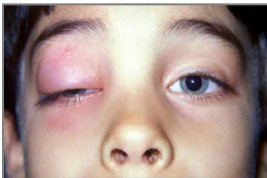With continuing, intense conflict activity (hanging conflict) a cauliflower-shaped growth (secretory type) forms in the tear gland. A large swelling (“**lacrimal gland tumor**”) bulges the eyelid outwards, as shown in this picture.



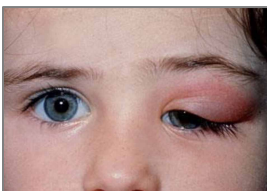NOTE: Baggy eyes are related to the kidney collecting tubules and an active abandonment or existence conflict. The skin beneath the eyes is very thin; this is why the water retention is more noticeable in that area.

HEALING PHASE: Following the conflict resolution (**CL**), fungi or mycobacteria such as TB bacteria remove the cells that are no longer needed. **Healing symptoms** are **swelling of the tear gland** caused by the edema (fluid accumulation) and **purulent eye discharge**. In **PCL-B**, the sticky pus dries up showing as yellowish **eye crust** around the eye(s). In conventional medicine, agglutinated and crusty eyelids are associated with “allergies” (see conjunctivitis).

The healing phase might be accompanied by an inflammation (**dacryoadenitis**) with redness and painful swelling of the lacrimal gland. With the SYNDROME, that is, with water retention as a result of an active abandonment or existence conflict, the swelling increases even more. The condition occurs quite often in children.

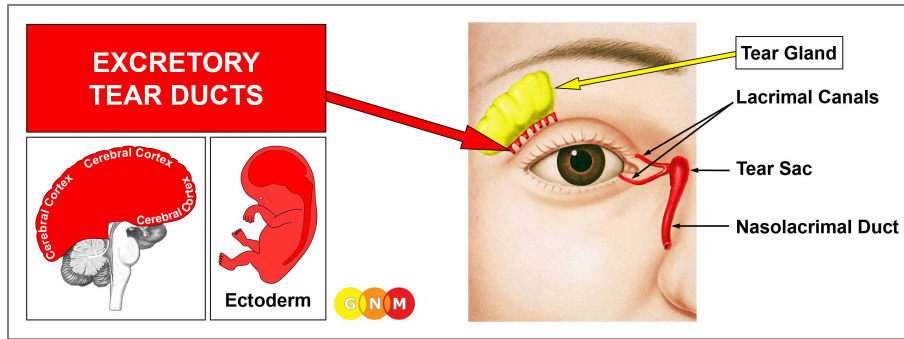


RIGHT eye: not being able to catch a visual morsel

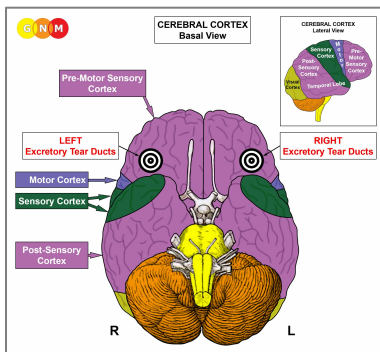


LEFT eye: not being able to eliminate a visual morsel

With a hanging healing due to constant conflict relapses more and more tear gland tissue is lost resulting in a decreased tear flow or a complete cessation of tear fluid production. The drying-up of the lacrimal flow (**xerophthalmia**) is termed **Sjogren's** or **Sicca syndrome** (see also dry eyes related to the excretory tear ducts, eyelid gland ducts, conjunctiva, and Sjogren's associated with a dry mouth).



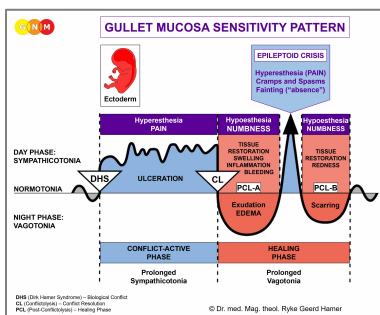
DEVELOPMENT AND FUNCTION OF THE TEAR DUCTS: The excretory tear ducts release the tear fluid produced by the tear glands into the top part of the conjunctiva and to the outer surface of the eyes. The lacrimal canals, which are two curved tubes located at the inner border of each eyelid, drain excess tears into the tear sac and through the nasolacrimal duct into the nasal cavity. The lining of the tear ducts consist of squamous epithelium, originates from the ectoderm and is therefore controlled from the cerebral cortex.



BRAIN LEVEL: The epithelial lining of the tear ducts is controlled from the **pre-motor sensory cortex** (part of the cerebral cortex). The right tear ducts are controlled from the left side of the cortex; the left tear ducts are controlled from the right cortical hemisphere (fronto-lateral-basal). Hence, there is a cross-over correlation from the brain to the organ.

NOTE: The control centers are located close to the brain relays of the eyelid gland ducts.

BIOLOGICAL CONFLICT: Similar to a separation conflict, the biological conflict linked to the tear ducts is “**wanting to be seen**” (not being noticed or overlooked, feeling visually ignored, not allowed to be seen) or “**not wanting to be seen**” (wanting to be invisible; a fear of getting caught, let’s say, in a criminal act, a sexual act, or when cheating).



The Biological Special Program of the **tear ducts** follows the **GULLET MUCOSA SENSITIVITY PATTERN** with hypersensitivity during the conflict-active phase and the Epileptoid Crisis and hyposensitivity in the healing phase.

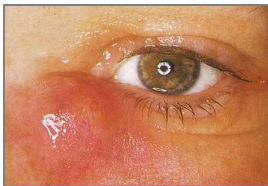CONFLICT-ACTIVE PHASE: **ulceration in the epithelial lining of the tear ducts** proportional to the degree and duration of conflict activity. The **biological purpose of the cell loss** is to widen the ducts in order to increase the tear flow. The “shiny eyes” makes the one who has been overlooked more eye-catching (in Nature, this is vital to attracting a mate). **Symptoms** are **teary eyes** and potentially painful pulling in the affected tear duct. With an acute conflict the tearing could be excessive (see also watery eyes related to the tear glands and the conjunctiva).

HEALING PHASE: During the first part of the healing phase (**PCL-A**) the tissue loss is replenished through **cell proliferation** with **swelling** due to the edema (fluid accumulation) in the healing area. Depending on the intensity of the conflict-active phase, the swelling could lead to an **obstruction of the tear ducts** causing **dry eyes**. A chronic condition because of continual conflict relapses is called **Sjogren's** or **Sicca syndrome** (see also dry eyes related to the tear glands, eyelid gland ducts, conjunctiva, and Sjogren's associated with a dry mouth). However, in this case, Sjogren's is not preceded by a swelling of the tear glands. An occlusion of the excretory tear ducts leads to an enlargement of the entire tear gland. The swelling is therefore frequently misdiagnosed as a lacrimal gland tumor.

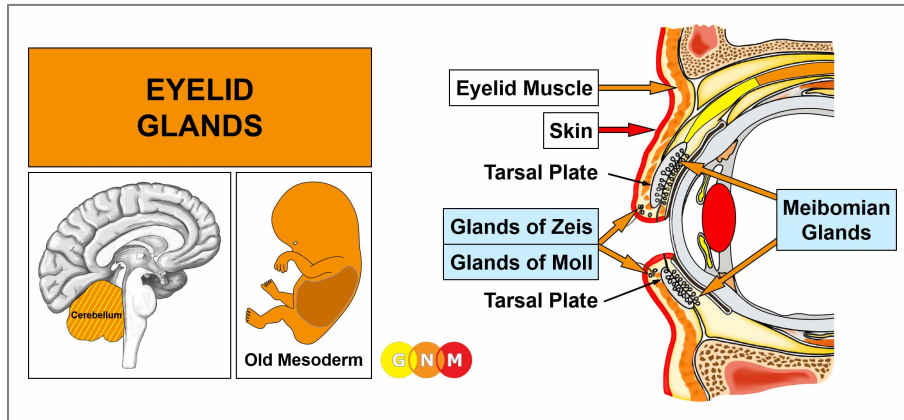
NOTE: Whether the tear ducts of the right or left eye are affected is determined by a person's handedness and whether the conflict is mother/child or partner-related.

Blocked tear ducts are quite common in infants. In infants and newborns the condition reveals the distress of "wanting to be seen" (not getting enough attention) or "not wanting to be seen" (too many visitors stopping by to see the new baby).

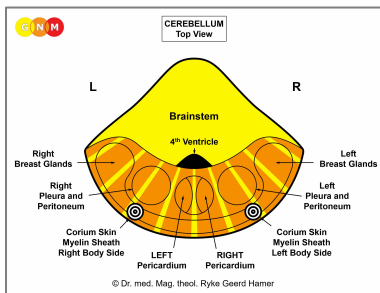
If the **nasolacrimal ducts** are blocked, tears cannot empty into the nasal cavity. The back-up of tears results in **watery and teary eyes**. An obstruction of the nasolacrimal duct with swelling and redness in the area between the eye and the nose, including the lacrimal sac, is called **dacryocystitis** ("tear sac infection").



This picture shows a child with a large swelling of the left nasolacrimal duct. If the child is right-handed, this indicates that the conflict (wanting to be seen or not wanting to be seen) was associated with the mother but has now been resolved. With concurrent water retention (the SYNDROME) due to an active abandonment conflict, the swelling increases considerably.



DEVELOPMENT AND FUNCTION OF THE EYELID GLANDS: The eyelids are movable folds of skin that cover and protect the eyes. The eyelashes attached to the upper and lower eyelids form a second protective shield against dust and other elements that could injure the eye. The outermost layers of the eyelid consist of epidermal tissue (outer skin) and fat tissue. Two eyelid muscles allow the opening and closing of the eyelids. The inside of the lids is lined with the conjunctiva. The main function of the eyelids is to keep the front surface of the eyeball and cornea moist. The **meibomian glands** and **glands of Zeis** are a special type of oil-producing sebaceous glands located at the rim of the upper and lower eyelids inside the tarsal plate. Close to the base of the eyelashes are also sweat glands, called the **glands of Moll** (both the sebaceous glands and sweat glands are embedded in the corium skin). The excretory ducts of the eyelid glands carry the oily sebum into the tear film to lubricate the eye during blinking. The eyelid glands originate from the old mesoderm and are therefore controlled from the cerebellum.



BRAIN LEVEL: In the **cerebellum**, the right eyelid glands are controlled from the left side of the brain; the left eyelid glands are controlled from the right brain hemisphere. Hence, there is a cross-over correlation from the brain to the organ.

NOTE: The eyelid glands are embedded in the corium skin of the eyelid. They are therefore controlled from the same brain relays (see also myelin sheath).

BIOLOGICAL CONFLICT: The biological conflict linked to the eyelid glands is an attack conflict, specifically, an **attack against the eye** (see also corium skin).

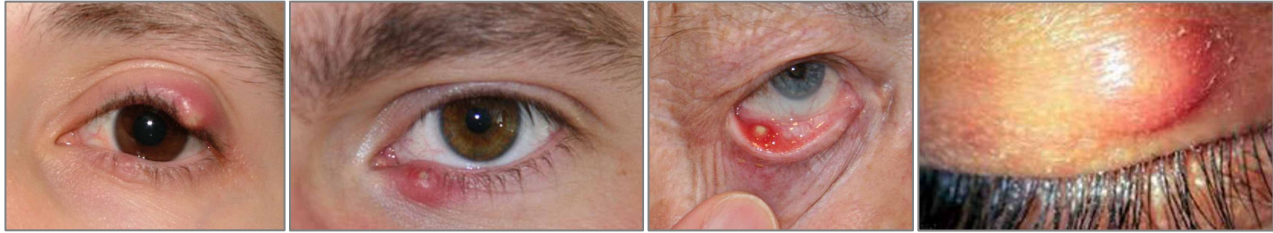In line with evolutionary reasoning, **attack conflicts** are the primary conflict theme associated with **cerebellum-controlled organs** deriving from the old mesoderm.

Dust, sand, or other particles (or a bug) hitting the eye can be registered as an attack conflict. In a figurative sense, the “attack” could be triggered by an insulting look (the “evil eye”) or a look of reproach. The conflict also relates to **feeling disfigured, soiled or “dirty” concerning the eyelids**. A “yucky” touch or kiss on the eye(s) might activate the conflict. Buying into the theory that touching the eyes after contact with a person who has a cold causes an “eye infection” only creates a predisposition for the conflict.

CONFLICT-ACTIVE PHASE: Starting with the DHS, during the conflict-active phase cells in the eyelid glands proliferate proportionally to the intensity of the conflict. The **biological purpose of the cell increase** is to provide an external reinforcement in order to protect the eyelid against further “attacks”. If the conflict persists, a **bulb-shaped growth** forms at the site, possibly diagnosed as an **eyelid tumor** (compare with a **melanoma** of the eyelid involving the corium skin).

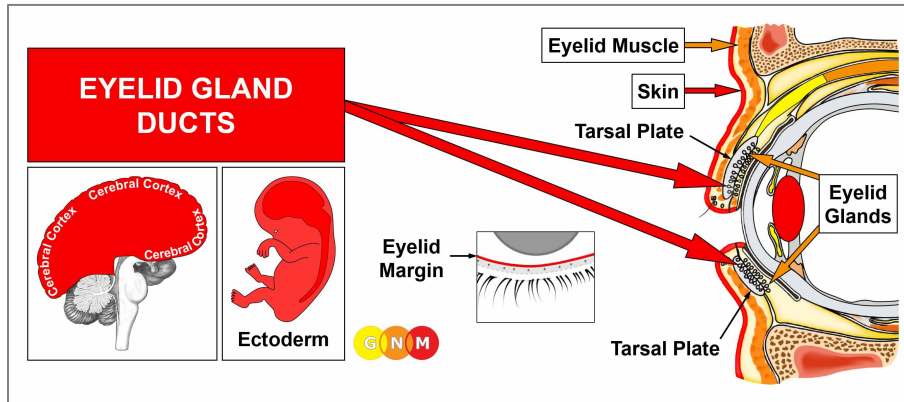
HEALING PHASE: Following the conflict resolution (CL), fungi or bacteria remove the cells that are no longer needed. During the healing process, the affected area swells up causing what is referred to as a **stye** (hordeola). The painful sore is **red and filled with pus**.

NOTE: Whether the right or left eyelid is affected is determined by a person's handedness and whether the conflict is mother/child or partner-related. A localized conflict affects the eye that was associated with the "attack".

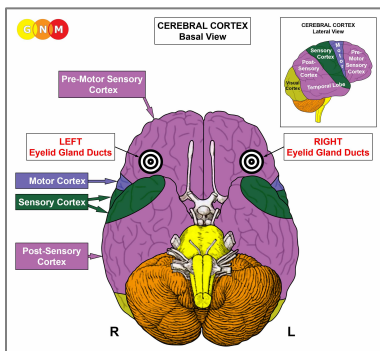


External styes involve the **glands of Moll**. They develop on the upper or lower lid margin at the base of the eyelashes. **Internal styes** relate to the **meibomian glands** and occur on the inside of the eyelid. If the meibomian glands become blocked and inflamed this results in a so-called **chalazion** (see right picture above), presenting as a granuloma that typically forms inside the upper eyelid. A chalazion is usually an indication of a hanging healing due to frequent conflict relapses. Feeling disfigured because of the appearance of the stye prolongs the healing phase.

If the required microbes are not available at the time, the additional cells remain. Eventually, the growth becomes encapsulated with connective tissue.



DEVELOPMENT AND FUNCTION OF THE EYELID GLAND DUCTS: The excretory ducts of the eyelid glands are located along the margin of the upper and lower eyelid. They carry the oily substance (sebum) produced in the eyelid glands into the tear film to keep the eyes moist and prevent tears from evaporating too quickly. The eyelid gland ducts consist of squamous epithelium, originate from the ectoderm and are therefore controlled from the cerebral cortex.

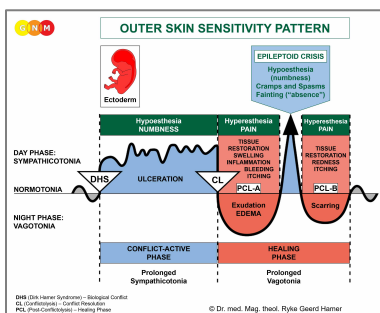


BRAIN LEVEL: The epithelial lining of the eyelid gland ducts is controlled from the **pre-motor sensory cortex** (part of the cerebral cortex). The right eyelid ducts are controlled from the left side of the cortex; the left eyelid ducts are controlled from the right cortical hemisphere (fronto-lateral-basal). Hence, there is a cross-over correlation from the brain to the organ.

NOTE: The control centers are located close to the brain relays of the excretory tear ducts.

BIOLOGICAL CONFLICT: The biological conflict linked to the eyelid gland ducts is a **visual separation conflict** experienced as **having lost sight of someone**, for example, of a loved one who has moved away, has left or has died (see also outer skin of eyelid, conjunctiva, cornea and lens). The conflict also relates to **not being allowed** or **not wanting to see someone** (a specific person or certain people). **NOTE:** A visual separation conflict only refers to people and animals such as a pet but not to objects (ring, car, favorite toy) or a home. This would instead involve the tear glands or the uvea of the eye.

In line with evolutionary reasoning, **territorial conflicts**, **sexual conflicts**, and **separation conflicts** are the primary conflict themes associated with organs of ectodermal origin, controlled from the **sensory, pre-motor sensory and post-sensory cortex**.

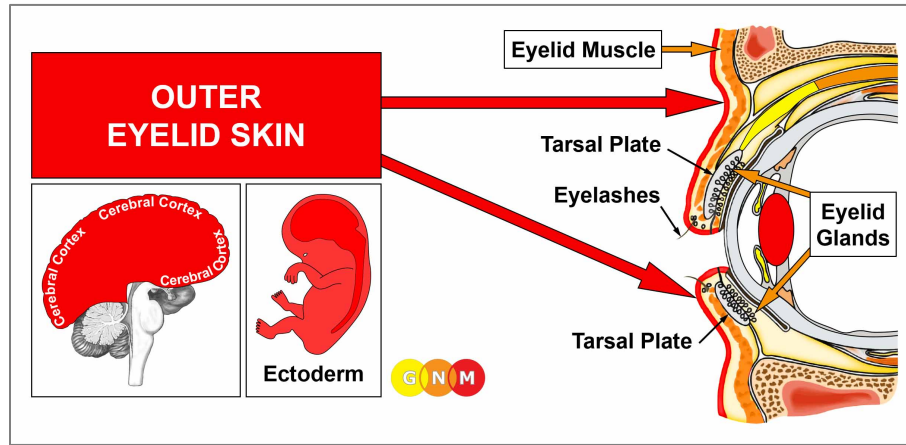


The Biological Special Program of the **eyelid gland ducts** follows the **OUTER SKIN SENSITIVITY PATTERN** with hyposensitivity during the conflict-active phase and the Epileptoid Crisis and hypersensitivity in the healing phase.

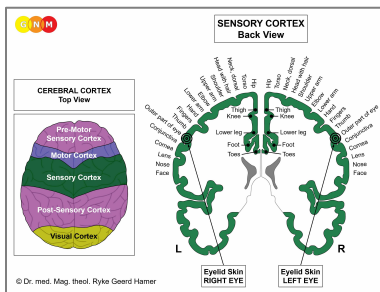
CONFLICT-ACTIVE PHASE: [ulceration in the eyelid gland ducts](#) proportional to the degree and duration of conflict activity. The **biological purpose of the cell loss** is to widen the ducts to increase the flow of lipids to keep the eye lubricated. In Nature, the clearer vision allows to quickly recognize a new mate that “strikes the eye”.

NOTE: Whether the ulceration occurs in the right or left eyelid gland ducts is determined by a person’s handedness and whether the conflict is mother/child or partner-related.

HEALING PHASE: During the first part of the healing phase ([PCL-A](#)) the tissue loss is replenished through **cell proliferation** with **swelling** due to the edema (fluid accumulation) in the healing area. The swelling might occlude the ducts (called “**Meibomian gland dysfunction**”). The blockage leads to a thinning of the lipid tear film layer and increased evaporation of tears causing **dry eyes**. If the symptom becomes chronic because of conflict relapses, then the condition is termed **Sjogren’s** or **Sicca syndrome** (see also dry eyes related to the tear glands, excretory tear ducts, conjunctiva, and Sjogren’s associated with a dry mouth).



DEVELOPMENT AND FUNCTION OF THE EYELID SKIN (EPIDERMIS): The eyelid skin consists of two layers: the corium skin and the outer skin (epidermis). The inside of the eyelid is lined with the conjunctiva. The outer eyelid skin, which is relatively thin, is supported by the tarsal plate to which the eyelid muscles are attached. The outer skin of the eyelid consists of squamous epithelium, originates from the ectoderm and is therefore controlled from the cerebral cortex.

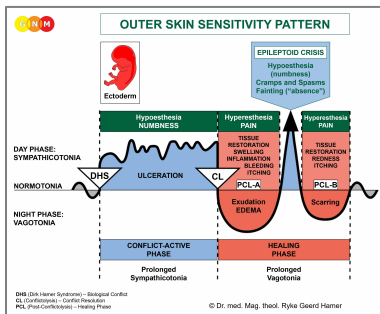


BRAIN LEVEL: The eyelid skin (epidermis) is controlled from the **sensory cortex** (part of the cerebral cortex). The right eyelid skin is controlled from the left side of the sensory cortex; the left eyelid skin is controlled from the right cortical hemisphere. Hence, there is a cross-over correlation from the brain to the organ (see GNM diagram showing the [sensory homunculus](#)).

BIOLOGICAL CONFLICT: The biological conflict linked to the eyelid skin is a **visual separation conflict**, specifically, **having lost sight of a person while one had the eyes closed**. For example, a loved one left or died unexpectedly while one was asleep; a mother lost sight of her infant while she was dozing off (compare with visual separation conflict related to the eyelid gland ducts, conjunctiva, cornea and lens). The outer skin (epidermis) of the eyelids also relates to a **loss of physical contact associated with the eyes**, for example, being no longer kissed on the eyelids (see separation conflict) as well as **wanting to separate from something or someone that touches the eyes** (an unwanted kiss on the eyelid, being blindfolded, “toxic” eye makeup).

In line with evolutionary reasoning, **territorial conflicts**, **sexual conflicts**, and **separation conflicts** are the primary conflict themes associated with organs of ectodermal origin, controlled from the [sensory](#), [pre-motor sensory](#) and [post-sensory cortex](#).

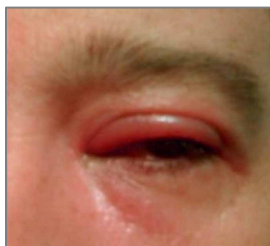NOTE: Whether the right or left eyelid is affected is determined by a person’s handedness and whether the conflict is mother/child or partner-related.



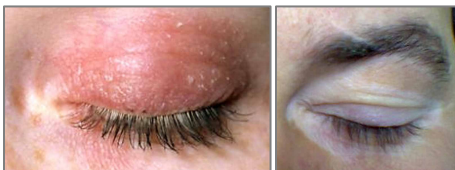The Biological Special Program of the **eyelid skin** follows the **OUTER SKIN SENSITIVITY PATTERN** with hyposensitivity during the conflict-active phase and the Epileptoid Crisis and hypersensitivity in the healing phase.

CONFLICT-ACTIVE PHASE: **ulceration in the epithelial lining of the eyelid skin** proportional to the degree of conflict activity. The ulcerative process makes the **eyelid skin dry and flaky**. When the lower eyelid is involved, the area below the eye is also affected. The Biological Special Program of the outer skin is always accompanied by a **short-term memory loss**, which serves the purpose to forget temporarily the one who is absent, here, specifically, the one who is out of sight.

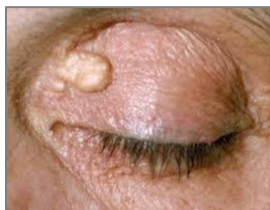HEALING PHASE: During the healing phase (in **PCL-A**) the ulcerated area is replenished with new cells. With an inflammation the condition is called **blepharitis**. The symptoms, including swelling, redness, a burning sensation and itching, range from mild to severe, depending on the intensity of the conflict-active phase.



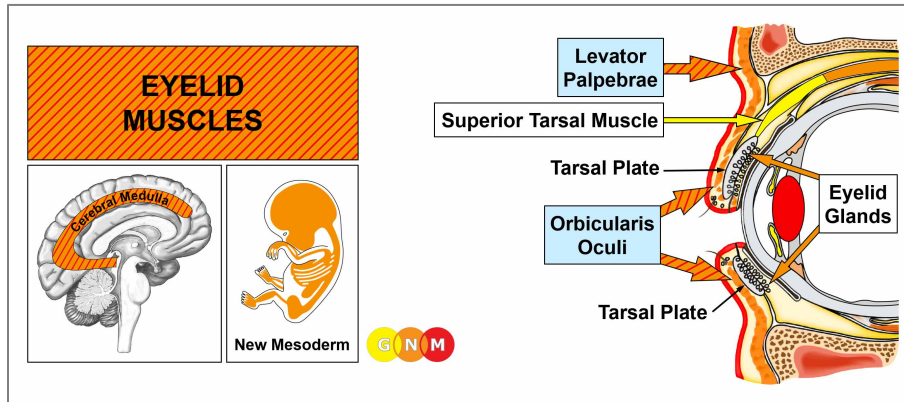
This picture shows **blepharitis** on the left eye, indicating the healing of a visual separation conflict associated with a partner if the person is left-handed. For a right-hander, the conflict relates to his/her mother or child.



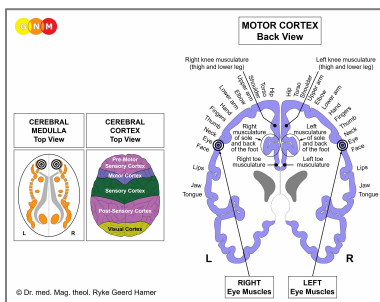
The healing process might present as a **rash on the eyelid (eyelid dermatitis)** or as **vitiligo** caused by a severe (visual) separation conflict (see right image) involving both the upper eyelid and the area below the eye.



A fat nodule on the eyelid, called a **xanthelasma**, is linked to a self-devaluation conflict associated with the eye (see fat tissue).



DEVELOPMENT AND FUNCTION OF THE EYELID MUSCLES: The eyelids contain three main muscles that control the movement of the eyelid. The two muscles involved in opening the upper eyelid are the **levator palpebrae muscle** (for voluntary opening) and the **superior tarsal muscle** (for involuntary opening). The **orbicularis oculi muscle** in the upper and lower eyelid controls the closing of the eye. As the eye elevates the levator muscle contracts and raises the eyelid; when the levator relaxes, the eyelid closes passively. Active eyelid closure to protect the eyes from injury and from excessive light (see pupil muscles) is achieved by the contraction of the orbicularis oculi. The eyelid muscles also control the blink reflexes. Blinking provides moisture to the eyes and the cornea by using tears (produced in the tear glands) and oily substances (secreted by the eyelid glands) to keep it from drying out. The eyelid muscles are attached to the tarsal plate that gives the eyelids shape and strength. The levator palpebrae and orbicularis oculi consist of striated muscles, originate from the new mesoderm and are controlled from the cerebral medulla and the motor cortex. The superior tarsal muscle is a smooth muscle.



BRAIN LEVEL: The levator palpebrae and orbicularis oculi have two control centers in the cerebrum. The trophic function of the muscles, responsible for the nutrition of the tissue, is controlled from the **cerebral medulla**; the ability to move the eyelids is controlled from the **motor cortex** (part of the cerebral cortex).

The eyelid muscles of the right eyelid are controlled from the left side of the cerebrum; the eyelid muscles of the left eyelid are controlled from the right cerebral hemisphere. Hence, there is a cross-over correlation from the brain to the organ (see GNM diagram showing the [motor homunculus](#)).

The smooth tarsal muscle is controlled from the [midbrain](#).

LEVATOR PALPEBRAE MUSCLE

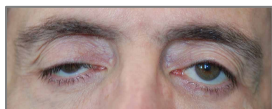BIOLOGICAL CONFLICT: The biological conflict linked to the levator palpebrae muscle is **not being able to keep the eye(s) open** (because of extreme fatigue, working night shifts) or **not having kept the eye(s) open** (having been wide awake) **at the right time** (having missed a red traffic light or an important visual message, e.g., on a blackboard or screen; having overlooked something of importance such as the small print of a contract). Certain professions, for example, policemen, detectives, pilots, professional drivers, people attending monitors and other devices used for observation are more susceptible to suffer this type of conflict. The levator muscle also relates to **not being allowed to keep the eye(s) open** (being prohibited to see or watch something) or **not wanting to keep the eye(s) open** (wanting to avoid seeing something distressing).

NOTE: Whether the levator muscle of the right or left eyelid is affected is determined by a person's handedness and whether the conflict is mother/child or partner-related.

CONFLICT-ACTIVE PHASE: **cell loss (necrosis) of the levator palpebrae** (controlled from the cerebral medulla) and, proportional to the degree of conflict activity, increasing **paralysis of the levator muscle** (controlled from the motor cortex).

NOTE: The striated muscles belong to the group of organs that respond to the related conflict with functional loss (see also Biological Special Programs of the islet cells of the pancreas (alpha islet cells and beta islet cells), inner ear (cochlea and vestibular organ), olfactory nerves, retina and vitreous body of the eyes) or hyperfunction (periosteum and thalamus).

Because of the weakness or paralysis of the levator muscle, responsible for raising the eyelid, the **upper eyelid sags** and fails to fully open. Depending on the intensity of the conflict, the droop may be barely noticeable or the eyelid can descend over the entire pupil. Yet, the eyelid doesn't close to cover the eye completely since the **tarsal muscle** prevents a complete closing. In medical terms, a drooping eyelid is called **blepharoptosis** (or **ptosis**). The inability to fully close the eyelid is termed **lagophthalmos**.



If the right upper eyelid droops, as seen in this image, the conflict is partner-related provided the person is right-handed.

HEALING PHASE: During the healing phase the levator muscle is reconstructed; the paralysis reaches into **PCL-A**. The Epileptoid Crisis manifests as eyelid muscle spasms (**blepharospasm**). Depending on the degree of the conflict-active phase, the rapid movement of the eyelid ranges from minor **eyelid fluttering** to strong **eyelid twitching or eyelid tics** (compare with facial tics). In **PCL-B** the function of the eyelid muscle returns to normal.

Excessive eye blinking also involves the levator muscle. The explicit **conflict linked to the blink reflex** is **feeling sussed out or figured out**, for example, when someone was caught cheating, lying, or playing tricks. The rapid blinking occurs during the Epileptoid Crisis and is typically triggered when setting on a track, for example, when the person is telling a lie.

ORBICULARIS OCULI MUSCLE

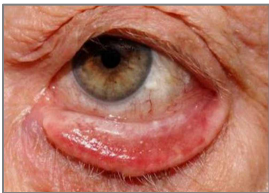BIOLOGICAL CONFLICT: The biological conflict linked to the orbicularis oculi muscle is **not being able to close the eyes** (in order to avoid seeing something unpleasant or undesirable; wanting to turn a “blind eye” to something) or **not having closed the eyes at the right time** (accidents caused by exposure to fire or explosives or by unsafe work with a welding device). The orbicularis oculi also relates to **not being allowed to close the eyes** (not being permitted to sleep or not getting enough sleep, for example, mothers with newborns, students working on last-minute term papers, shift workers, long-distance truck drivers) or **not wanting to close the eyes** (kids refusing to nap).

NOTE: Whether the orbicularis muscle of right or left eyelid is affected is determined by a person’s handedness and whether the conflict is mother/child or partner-related.

CONFLICT-ACTIVE PHASE: cell loss (necrosis) of the orbicularis oculi of the upper or lower eyelid (controlled from the cerebral medulla) and, proportional to the degree of conflict activity, increasing **paralysis of the orbicularis oculi muscle** (controlled from the motor cortex).

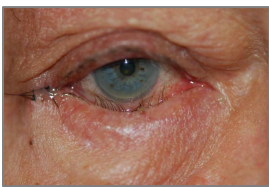
NOTE: The striated muscles belong to the group of organs that respond to the related conflict with functional loss (see also Biological Special Programs of the islet cells of the pancreas (alpha islet cells and beta islet cells), inner ear (cochlea and vestibular organ), olfactory nerves, retina and vitreous body of the eyes) or hyperfunction (periosteum and thalamus).

Because of the weakness or paralysis of the orbicularis oculi muscle, responsible for closing the eyelid, the upper and lower **eyelid cannot be closed properly** (see also facial paralysis with the inability to close the eye on the paralyzed side. The orbicularis oculi and the facial muscles are both supplied by the facial nerve).

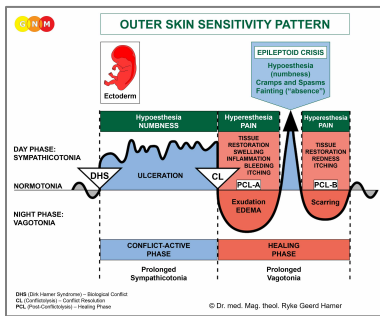


If the **lower eyelid** is affected, the **decreased tension** of the orbicularis oculi causes the lower lid to sag outwards, away from the eye. This condition is known as an **ectropion** (see picture). If the upper eyelid is affected, the **upper eyelid droops** (compare with ptosis related to the biological conflict of the levator palpebrae muscle).

HEALING PHASE: During the healing phase the orbicularis oculi muscle is reconstructed; the paralysis reaches into **PCL-A**. The Epileptoid Crisis manifests as eye muscle spasms (**blepharospasm**) of the upper or lower eyelid. Depending on the degree of the conflict-active phase, the rapid movement of the eyelid ranges from minor **eyelid fluttering** to strong **eyelid twitching or eyelid tics** (see also facial tics). In **PCL-B** the function of the eyelid muscle returns to normal.



With a hanging healing due to continual conflict relapses the prolonged **increased tension** of the orbicularis oculi of the **lower eyelid** causes the eyelid to fold inwards. This condition, called an **entropion**, is quite uncomfortable since the eyelashes constantly rub against the eye leading to redness and irritation of the eye.




The Biological Special Programs of the **conjunctiva, cornea, and lens** follow the **OUTER SKIN SENSITIVITY PATTERN** with hyposensitivity during the conflict-active phase and the Epileptoid Crisis and hypersensitivity in the healing phase.

CONFLICT-ACTIVE PHASE: **ulceration in the conjunctiva, cornea, or lens.** In the lens, the **loss of crystalline cells** improves the reception of light and therefore the visual acuity with the **biological purpose** that the person fading from one's sight will be longer visible. The enhanced distant vision also increases the chance of detecting a lost "pack member" in the far distance. The Biological Special Programs of the conjunctiva, cornea, and lens are accompanied by a **short-term memory loss**, which serves the purpose to forget temporarily the one who is out of sight (see separation conflict related to the skin).

NOTE: Whether the conjunctiva, cornea, or lens of the right or left eye is affected is determined by a person's handedness and whether the conflict is mother/child or partner-related.

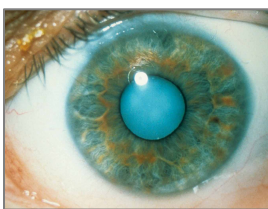
In the **conjunctiva**, the **ulceration makes the eye(s) dry** (see also dry eyes related to the tear glands, excretory tear ducts, and eyelid gland ducts).



In the **cornea**, the prolonged ulceration leads to a so-called **keratoconus** in which the normally round cornea becomes thin and begins to bulge into a cone-like shape. The asymmetrical, unequal shape of the cornea causes **astigmatism** with **distorted and double vision** (see also healing phase). Typical is a constant blur for both near and distant vision. Because of the cornea's function to refract light, people with astigmatism are **light sensitive**.

If the cornea's angle of curvature becomes too steep, this causes **nearsightedness** or **myopia** (see also smooth ciliary muscles and retina). **Farsightedness** or **hyperopia** occurs when the cornea has too flat of an angle (see also striated ciliary muscles and retina).

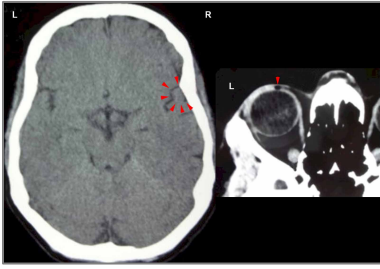
HEALING PHASE: During the healing phase the cell loss is restored and replenished.



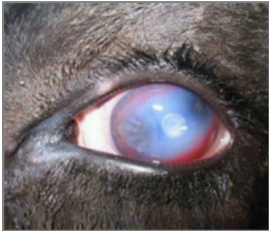
Concerning the **lens**, the healing process manifests as **clouding of the lens** with a **fuzzy or hazy vision** (there are no symptoms in the conflict-active phase). An intense healing phase is accompanied by pain and discomfort. If the healing phase cannot be complete because of continuous conflict relapses, the clouding remains (see picture). A permanent opacity of the lens is called a "**grey cataract**" (compare with "green cataract" related to the vitreous body).

According to conventional medicine, cataracts are considered a normal part of the aging process even though not every person develops a cataract at an older age. From a GNM point of view, it is rather the increasing incidences of visual separation conflicts – from a parent, a spouse, a long-time companion or friend – why cataracts are much more common in older people.

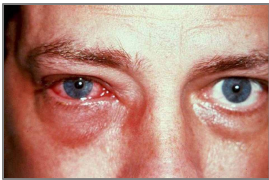In the **cornea**, the healing symptom presents as **blurry vision**. With an inflammation the condition is called **keratitis**. Symptoms are pain and redness. With constant conflict relapses an **astigmatism** (see conflict-active phase) becomes permanent due to recurrent scarring processes in the cornea.



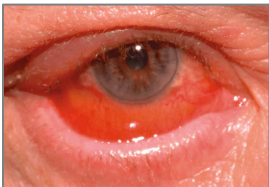In the left image we see a Hamer Focus (in [PCL-A](#)) on the right side of the sensory cortex in the area that controls the cornea of the left eye ([view the GNM diagram](#)). A look at the orbit section (right image) confirms that a healing process in the cornea (red arrow) is underway.



This picture shows a dog with keratitis in the left eye. If the dog is left-pawed, this indicates that the visual separation conflict is linked to a “partner” such as his master or another dog or animal friend.

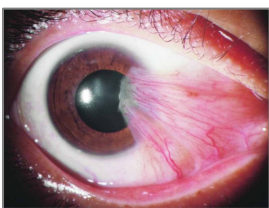


Conjunctivitis (pink eye) with red, burning, itchy, and watery eyes occurs when the **conjunctiva** is in healing (see also watery eyes related to the tear glands or nasolacrimal ducts). The inflammation often involves the inside of the eyelids (compare with blepharitis related to the eyelid skin). The symptoms range from mild to severe, depending on the intensity of the conflict-active phase. For a right-handed person, the right eye is affected if the visual separation conflict is associated with a partner; if the person is left-handed the conflict is mother/child-related.

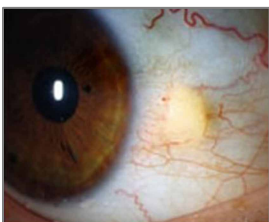


Chemosis is the clinical term for the swelling (edema) and inflammation of the conjunctiva. With the SYNDROME (water retention as a result of an active abandonment or existence conflict) the swelling increases considerably.

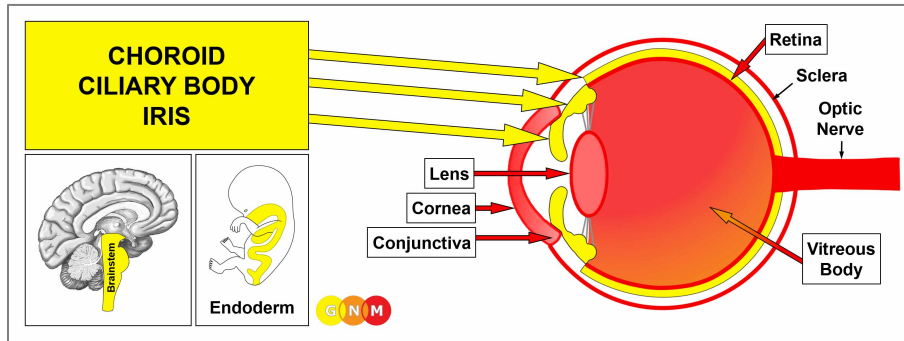
Conjunctivitis and chemosis are commonly associated with “allergies” and assumed to be caused by the exposure to pollen. With concurrent cold symptoms such as a runny nose, the “allergy” is called “**hay fever**”. In GNM terms, the combination of the symptoms is a sign that the healing phase of a visual separation conflict and of “scent or stink conflict” related to the nasal mucosa happen simultaneously. Agglutinated and crusty eyelids reveal that an additional “visual morsel conflict” involving the tear glands has also been resolved.



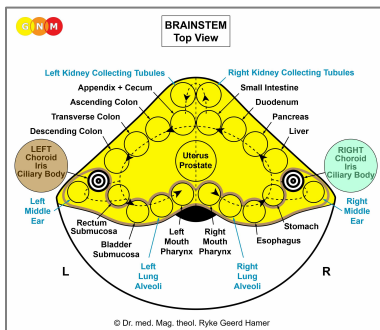
A so-called **pterygium** is the result of a prolonged healing process (hanging healing) with a buildup of scar tissue that grows from the conjunctiva towards the center of the eye onto the cornea.



A **pinguecula** (“eye bump”) is a yellowish or white patch growing on the conjunctiva, also a result of a hanging healing due to continuous conflict relapses. Unlike a pterygium, the growth does not reach into the cornea.



DEVELOPMENT AND FUNCTION OF THE CHOROID, IRIS, AND CILIARY BODY: The choroid, iris, and ciliary body are collectively called the uvea. The **choroid** lines the inner surface of the eyeball and supplies the underlying retina with nutrition. The **iris** in the front of the eye is part of the choroid. The iris helps to regulate the amount of light that enters the eye (see also cornea) and is therefore functionally closely tied to the pupils. The **ciliary body** connects the choroid with the iris. The ciliary body produces a watery fluid (intraocular fluid or aqueous humor) that fills the **anterior and posterior chamber** of the eyeball. The function of the intraocular fluid is to maintain the intraocular pressure (see also vitreous body). The ciliary body contains the ciliary muscles that control the shape of the lens to allow clear vision. The uvea contains considerable amounts of melanin pigments to protect the eye from excess light (see also corium skin). In the iris, the quantity of melanin determines the color of the iris ranging from brown to blue. In evolutionary terms, the choroid, iris, and ciliary body constitute the **primordial eyecup** that developed from the intestinal mucosa of the original gullet (see also pupil muscles and ciliary muscles). Like the intestinal cells that absorb and digest the “food morsel”, the biological function of the uvea is to “absorb” (absorptive quality) and to “digest” (secretory quality) the “visual morsel”. The choroid, iris, and ciliary body consist of intestinal cylinder epithelium, derive from the endoderm and are therefore controlled from the brainstem.



BRAIN LEVEL: In the **brainstem**, the choroid, iris, and ciliary body have two control centers that are positioned in close vicinity to the brain relays that control the organs of the alimentary canal.

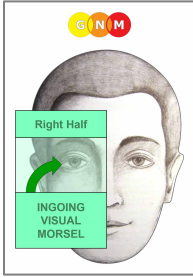
The choroid, iris, and ciliary body of the right eye are controlled from the right side of the brainstem; the choroid, iris, and ciliary body of the left eye are controlled from the left brainstem hemisphere. There is no cross-over correlation from the brain to the organ.

NOTE: The optic nerve emerged from the brain relays that innervated the primordial eyecup (today’s choroid).

BIOLOGICAL CONFLICT: The biological conflict linked to the choroid, iris, and ciliary body is a “**morsel conflict**”, specifically, a conflict related to a “**visual morsel**” (see also tear glands).

In line with evolutionary reasoning, **morsel conflicts** are the primary conflict theme associated with **brainstem-controlled organs** deriving from the endoderm.


UVEA OF THE RIGHT EYE



Equivalent to the right half of the mouth and pharynx, the **choroid, iris, and ciliary body of the right eye** correlate to an “**ingoing morsel**” and to “**not being able to catch a visual morsel**”.

In biological terms, the ingoing “visual morsel” is equal to nourishment (see also sound morsel related to the middle ear and Eustachian tubes). Figuratively speaking, the conflict experience is “I want to devour what I desire with my eyes”. What one is “drooling” to see can relate to anyone or anything one is not or no longer able to see or not allowed to see, for example, a beloved person or a home one had lost. It might also be about something one had anticipated to see (a certain person, paper money, a toy, a TV program, a vacation resort) and could unexpectedly not visually “grab” or “catch sight of”. The fear of becoming blind (“not being able to catch a visual morsel”) triggered, for example, by an MS diagnosis, a diabetes diagnosis (see diabetic retinopathy), or the negative prognosis of a macular degeneration could also prompt the conflict.

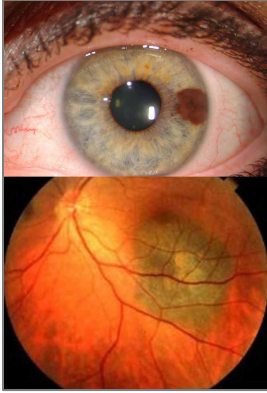
UVEA OF THE LEFT EYE



Equivalent to the left half of the mouth and pharynx, the **choroid, iris, and ciliary body of the left eye** correspond to an “**outgoing morsel**” and to “**not being able to eliminate a visual morsel**” (originally, the feces morsel).

Such an undesired “visual morsel” relates to any “eyesore” one wants to get rid of (“I can’t bear to look at this”) or images one wants to erase from one’s memory. Eye-witnessing an accident or crime, seeing a spouse or partner with someone else, or watching something disturbing on TV can activate the conflict. Children suffer the distress when “catching” their parents or witnessing family abuse. The unwanted “visual morsel” could also be a person one does no longer want to see (a relative, parent, ex-spouse, “friend”, colleague, teacher, visitor).

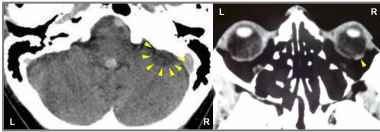
CONFLICT-ACTIVE PHASE: Starting with the DHS, during the conflict-active phase cells in the choroid, iris, or ciliary body proliferate proportionally to the intensity of the conflict. The **biological purpose of the cell increase** is to be better able to absorb (right eye) or expel (left eye) the “visual morsel”. Which one of the tissues is affected is random.



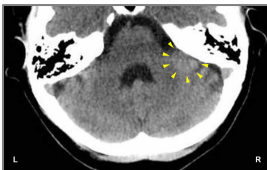
With prolonged conflict activity a flat (resorptive type) or compact (secretory type) growth develops from the pigmented cells of the uvea. In conventional medicine, this is called a **ciliary body melanoma**, **iris melanoma** (upper picture), **choroid melanoma** (lower picture) or, generally, an **ocular melanoma**. Histologically, the term “melanoma” is actually incorrect since the uvea does not have a corium skin; the term “adenoma” would be more applicable. The same pertains to what is called “**retinitis pigmentosa**” which is, according to Dr. Hamer’s findings, a condition of the choroid (choroid adenoma) rather than of the retina.

HEALING PHASE: Following the conflict resolution (**CL**), fungi or mycobacteria such as TB bacteria remove the cells that are no longer required.

In the **choroid**, the tubercular lesions are visible as white spots behind the retina; they disappear with the completion of the healing phase. A continuous decomposing process, however, creates **caverns in the choroid** that are eventually filled with calcium deposits. The loss of pigmentation causes **light sensitivity**.

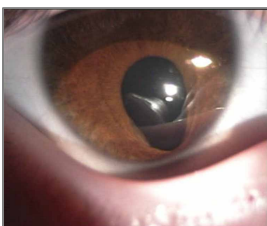


On the left image we see a brain edema (in **PCL-A**) on the right side of the brainstem in the area that controls the choroid of the right eye (view the **GNM diagram**). On a brain scan, the fluid accumulation presents as dark (hypodense). The orbit section (right image) shows the presence of TB bacteria (yellow arrow).

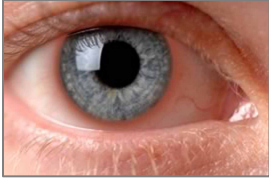


During the second part of the healing phase (in **PCL-B**) glial cells proliferate at the site to restore the brain relay where the visual morsel conflict was registered. On a brain CT, the glia accumulation shows as white (hyperdense). In conventional medicine, the glia buildup is wrongly believed to be a “brain tumor”.

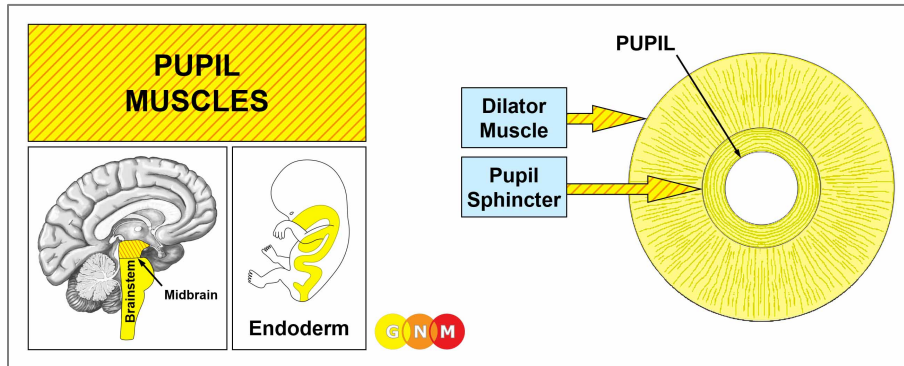
NOTE: The optic nerve is a paired nerve that transmits visual information from the retina to the **visual cortex** at the back of the brain. It is one of the two cranial nerves (the other being the olfactory nerve innervating the **olfactory bulb**) that are a protrusion of the cerebrum. The optic nerves are largely composed of glial cells. An enlargement of the optic nerve is therefore referred to as an “optic nerve glioma”, or optic neuroma, which can arise anywhere along the pathway of the optic nerve. In GNM terms, an **optic neuroma** that develops in the brainstem (in **PCL-B**) originates from a “visual morsel” conflict involving the choroid (compare with acoustic neuroma related to a “sound morsel” and the acoustic nerve).



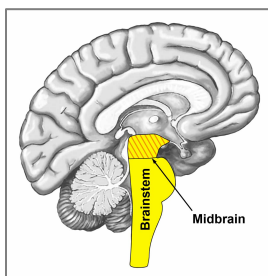
In the **iris**, lasting tuberculosis leads eventually to a loss of iris tissue (**coloboma**) with the result that the pupil becomes larger at that area.



Iritis is a painful inflammation of the iris. The condition can occur together with **choroiditis**, an inflammation of the choroid. **Uveitis** involves the entire uvea.



DEVELOPMENT AND FUNCTION OF THE PUPIL MUSCLES: The pupil is the black round hole in the center of the iris. Its blackness is due to the lack of reflection of light from within the eye. The pupils consist of two muscles that regulate the amount of light that enters the eye. The **dilator muscle** widens the pupils allowing more light to pass through the eyes; the **pupil sphincter** narrows the pupils so that less light reaches the retina. In bright light the sphincter muscle contracts while the dilator muscle relaxes, making the aperture smaller. In dim light the sphincter muscle relaxes while the dilator muscle contracts, opening up the aperture. The dilator muscle is supplied by sympathetic nerves, which is why the pupils become large during stress (sympathicotonia) or sexual arousal. The pupil sphincter is supplied by parasympathetic nerves making the pupils small during relaxation (vagotonia). In evolutionary terms, the pupil muscles belong to the primordial eyecup that developed from intestinal cells (see also ciliary muscles and ciliary body). Like the intestinal muscles that move the “food morsel” along the intestinal canal through peristaltic motion, the pupil muscles contract and expand in response to the “light morsel”. The dilator muscle and pupil sphincter are composed of smooth muscles, derive therefore from the endoderm and are controlled from the midbrain.



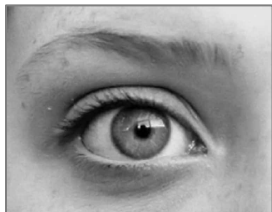
BRAIN LEVEL: The pupil muscles are controlled from the **midbrain**, located at the outermost part of the brainstem.

BIOLOGICAL CONFLICT: According to their function, the pupil muscles are linked to a **light-related morsel conflict** – literally or figuratively.

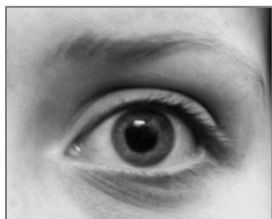The **dilator muscle** of the **right pupil** corresponds to the conflict of “**not enough light to catch a morsel**”. This can relate to any important information (on a board or screen), warnings (“watch your step!”), signs (a road sign) or a person that was overlooked because of insufficient light. The **left pupil** correlates to “**not enough light to eliminate a morsel**”, for example, if one is not able to avert a dangerous situation (an accident, an attack) because it was too dark (compare with the distress of sudden long darkness associated with the pineal gland). In a figurative sense, the conflict can be provoked if one is unexpectedly not in the “limelight” or not presented in the “proper light”.

The **pupil sphincter** of the **right pupil** corresponds to the conflict of “**too much light to catch a morsel**” (a visual morsel that is of importance), let’s say, because one was blinded by the sun or by bright light such as headlights, spotlights, a searchlight, a (police) flashlight, or a welding device. The **left pupil** correlates to “**too much light to eliminate a morsel**”, for example, if one is not able to prevent a dangerous situation because it was too bright. In a figurative sense, the conflict could be triggered when the “spotlight” is turned on someone, bringing something unpleasant or embarrassing “to light”.

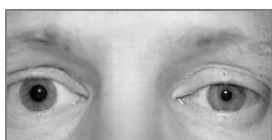CONFLICT-ACTIVE PHASE:



The distress of “too much light” causes a sustained **hypertonus of the pupil sphincter**. The **biological purpose of the increased muscle tension** is to make the pupil smaller so that less light enters the eye. A prolonged or excessive **constriction of the pupil** is called **myosis**.

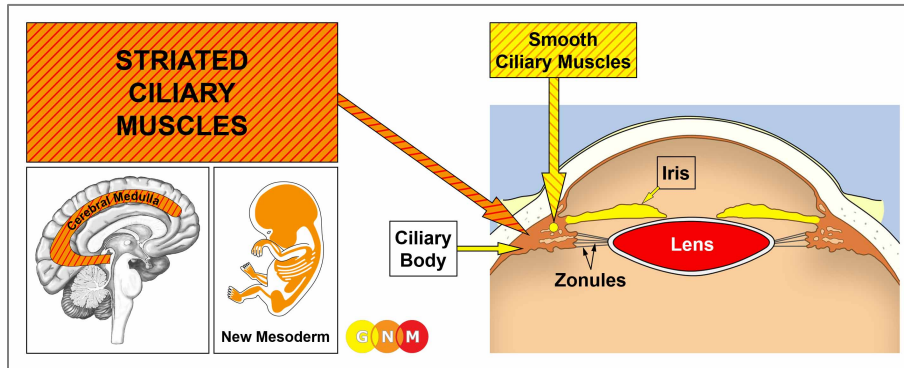


The distress of “not enough light” causes a sustained **hypertonus of the dilator muscle**. The **biological purpose of the increased muscle tension** is to widen the pupil so that more light can pass through the eye. A prolonged or excessive **dilation of the pupil** is called **mydriasis**, which causes **light sensitivity**.

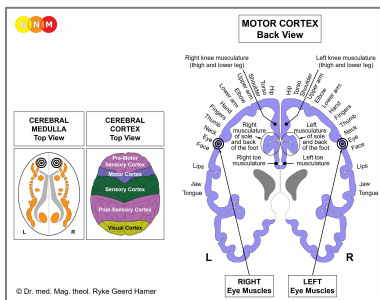


An enlargement of the right pupil, as seen in this picture, reveals that the person is conflict active with “not enough light to catch a morsel”.

HEALING PHASE: During the healing phase the muscle tension goes back to normal. The Epileptoid Crisis presents as **pupil spasms** (compare with fluttering of the lens and nystagmus related to the extraocular muscles).



DEVELOPMENT AND FUNCTION OF THE CILIARY MUSCLES: The ciliary body contains a set of ciliary muscles that regulate the changing of the lens shape (accommodation) to produce a clear vision at varying distances. Ligaments, called zonules, connect the ciliary body with the lens to hold it in place. The contraction of the ciliary muscles relaxes the zonules causing the lens to become rounder, which increases its power to focus on nearby objects. When the ciliary muscles relax, the zonules pull the edges of the lens making it flatter to see objects in a far distance. The ciliary muscles are composed of smooth muscles (involuntary) and striated muscles (voluntary). In evolutionary terms, the smooth ciliary muscles belong to the **primordial eyecup** (see ciliary body and pupil muscles); they therefore originate from the endoderm and are controlled from the midbrain. The striated ciliary muscles derive from the new mesoderm and are controlled from the cerebral medulla and the motor cortex.



BRAIN LEVEL: The striated ciliary muscles have two control centers in the cerebrum. The trophic function of the muscles, responsible for the nutrition of the tissue, is controlled from the **cerebral medulla**; the ability to contract and relax the ciliary muscles is controlled from the **motor cortex** (part of the cerebral cortex). The striated ciliary muscle of the right eye is controlled from the left side of the cerebrum; the ciliary muscle of the left eye is controlled from the right cerebral hemisphere. Hence, there is a cross-over correlation from the brain to the organ (see GNM diagram showing the **motor homunculus**). The smooth ciliary muscles are controlled from the **midbrain**, located at the outermost part of the brainstem.

NOTE: The striated ciliary muscles and extraocular muscles share the same brain relays.

SMOOTH CILIARY MUSCLES

BIOLOGICAL CONFLICT: The biological conflict linked to the smooth ciliary muscles is “**not being able to see what is close**” (difficulties reading small print, for example, in a newspaper, on a blackboard, computer screen, or phone screen), “**not being allowed to see what is close**”, or “**not wanting to see what is close**” (not wanting to see what takes place right in front of one’s eyes, e.g., family violence; wanting to play outside rather than doing homework).

CONFLICT-ACTIVE PHASE: sustained **hypertonus** (contraction) of the smooth ciliary muscles causing a relaxed tension on the zonules and subsequently a curved lens, which serves the **biological purpose** to be better able to see what is close. Ongoing conflict activity results in **nearsightedness** or **myopia** (see also cornea and retina). **NOTE:** Working with fine tools (needlework) or “staring at the screen all day” strains the focusing power of the ciliary muscles leading over time to nearsightedness – without a DHS.

HEALING PHASE: During the healing phase the muscle tension goes back to normal. The Epileptoid Crisis manifests as **fluttering of the lens** to which the ciliary muscles or rather the zonules are attached (compare with pupil spasms and nystagmus related to the extraocular muscles).

STRIATED CILIARY MUSCLES

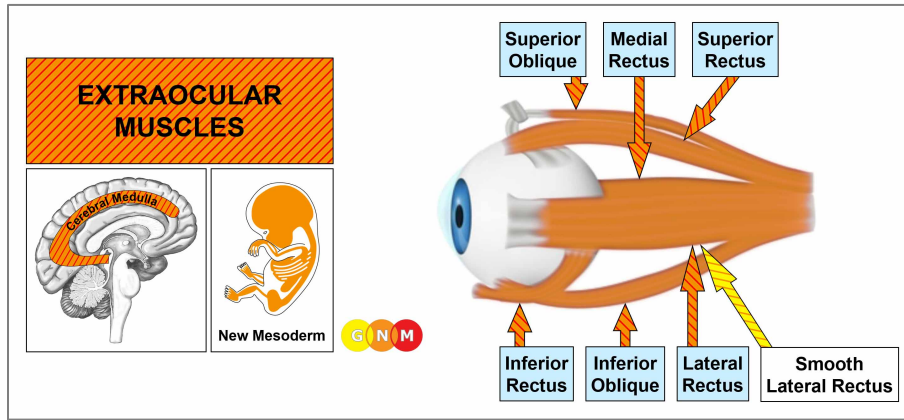
BIOLOGICAL CONFLICT: The biological conflict linked to the striated ciliary muscles is “**not being able to see what is in the distance**” (a person or object is too far away to be recognized or identified; difficulties reading a sign because it is too far away) or “**not being allowed to see what is far away**” (not being permitted to visit someone or to go on a journey) but also “**not wanting to see what is in the distance**” (a person who is leaving).

CONFLICT-ACTIVE PHASE: **cell loss (necrosis) of ciliary muscles** (controlled from the cerebral medulla) and, proportional to the degree of conflict activity, increasing **paralysis** (weakness) of the striated ciliary muscles (controlled from the motor cortex). This causes the zonules to tighten making the lens flat, which serves the **biological purpose** to be better able to see what is far away. Prolonged conflict activity results in **farsightedness** or **hyperopia** (see also lens and retina).

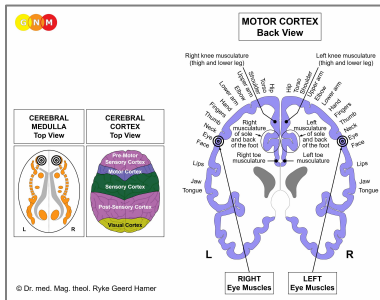
NOTE: The striated muscles belong to the group of organs that respond to the related conflict with functional loss (see also Biological Special Programs of the islet cells of the pancreas (alpha islet cells and beta islet cells), inner ear (cochlea and vestibular organ), olfactory nerves, retina and vitreous body of the eyes) or hyperfunction (periosteum and thalamus).

HEALING PHASE: During the healing phase the necrosis is reconstructed. Since the ciliary muscle is attached to the lens through the zonules, the Epileptoid Crisis manifests as a **fluttering of the lens** (compare with pupil spasms and nystagmus related to the extraocular muscles).

At the end of the healing phase, the ciliary muscle will be stronger than before. This principle, namely that an organ works more efficiently after healing has been complete, applies without exception to all **cerebral medulla-controlled organs**.



DEVELOPMENT AND FUNCTION OF THE EXTRAOCULAR MUSCLES: The extraocular muscles are six small muscles that surround the eye and control its movement. Four rectus (“straight”) muscles regulate the movement of the eyeball from left to right and up and down: the **superior rectus** moves the eye upward, the **inferior rectus** moves the eye downward, the **medial rectus** moves the eye inward (towards the nose), and the **lateral rectus** moves the eye outward (away from the nose). The two oblique muscles are primarily responsible for rotating the eyes: the **superior oblique** rotates the eye inward and downward, the **inferior oblique** rotates the eye outward and upward. The extraocular muscles are mainly made of striated muscles originating from the new mesoderm. They are controlled from the cerebral medulla and the motor cortex (compare with smooth lateral rectus muscle).



BRAIN LEVEL: The extraocular muscles have two control centers in the cerebrum. The trophic function of the muscles, responsible for the nutrition of the tissue, is controlled from the **cerebral medulla**; the ability to move the eye is controlled from the **motor cortex** (part of the cerebral cortex).

The right eye muscles are controlled from the left side of the cerebrum; the left eye muscles are controlled from the right cerebral hemisphere. Hence, there is a cross-over correlation from the brain to the organ (see GNM diagram showing the **motor homunculus**).

NOTE: The extraocular muscles and striated ciliary muscles share the same brain relays.

BIOLOGICAL CONFLICT: The biological conflict linked to the extraocular muscles is “**not wanting to look in a certain direction**” because of something distressing “there”. Newborns, for example, suffer the conflict when they are blinded by bright fluorescent light in the delivery room. The extraocular muscles also correspond to “**not being allowed to look there**” (a student is caught cheating while he was trying to copy the exam from his neighbor) and “**not being able to look there**” (an infant is unable to look towards the mother).

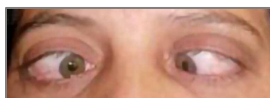CONFLICT-ACTIVE PHASE: **cell loss (necrosis) of muscle tissue** (controlled from the cerebral medulla) and, proportional to the degree of conflict activity, increasing **paralysis of the affected eye muscle** (controlled from the motor cortex).

NOTE: The striated muscles belong to the group of organs that respond to the related conflict with functional loss (see also Biological Special Programs of the islet cells of the pancreas (alpha islet cells and beta islet cells), inner ear (cochlea and vestibular organ), olfactory nerves, retina and vitreous body of the eyes) or hyperfunction (periosteum and thalamus).

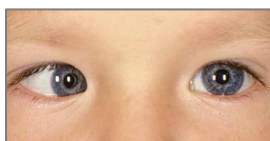The paralysis or weakness of the eye muscle causes **strabismus**, the inability to attain binocular vision (see also strabismus caused by the damage of the oculomotor nerve due to a pineal gland tumor). Depending on the exact nature of the conflict, one or both eyes deviate inward, outward, upward or downward.

NOTE: Whether the eye muscle of the right or left eye (or both) is affected is determined by a person's handedness and whether the conflict is mother/child or partner-related. A localized conflict affects the eye muscle that is associated with the specific conflict situation.

Strabismus esotropia (cross-eyed): one or both eyes deviate inward.

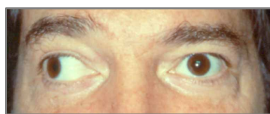

Both eyes turn inward and downward because the eye muscles that pull the eyes outwards (lateral rectus) and upwards (superior rectus) are paralyzed.



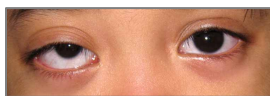
The right eye turns inward because the eye muscle that pulls the eye outward (lateral rectus) is paralyzed. If the person, let's say a child, is left-handed then the conflict ("didn't want, was not allowed, or was not able to look to the right") is associated with the mother or situation-related. For a right-hander, the conflict is partner-related.

Strabismus exotropia (wall-eyed): one or both eyes deviate outward.



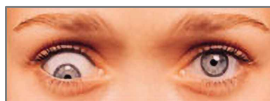The right eye turns outward because the eye muscle that pulls the eye inward (medial rectus) is paralyzed. If the person is right-handed then the conflict ("didn't want, was not allowed, or was not able to look to the left") is associated with a partner or situation-related. For a left-hander, the conflict is mother or child-related.

Strabismus hypertropia: one or both eyes deviate upward.



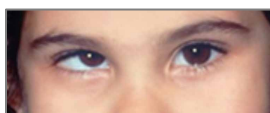The right eye turns upward because the eye muscle that pulls the eye downward (inferior rectus) is paralyzed. If the person is left-handed then the conflict ("didn't want, was not allowed, or was not able to look downward") is associated with his/her mother or child or situation-related. For a right-hander, the conflict is partner-related.

Strabismus hypotropia: one or both eyes deviate downward.



The right eye turns downward because the eye muscle that pulls the eye upward (superior rectus) is paralyzed. If the person is right-handed then the conflict ("didn't want, was not allowed, or was not able to look upward") is associated with a partner or situation-related. For a left-hander, the conflict is mother or child-related.

Cyclophoria is a type of strabismus in which the axis of one or both eyes rotates inward or outward due to the paralysis of the oblique muscles.

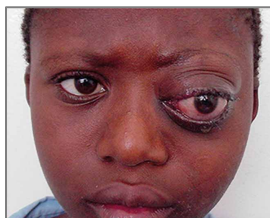

If the right eye is affected and the person is right-handed, then the conflict ("didn't want, was not allowed, or was not able to look downward and to the right") is associated with a partner or situation-related. For a left-hander, the conflict is mother/child-related.

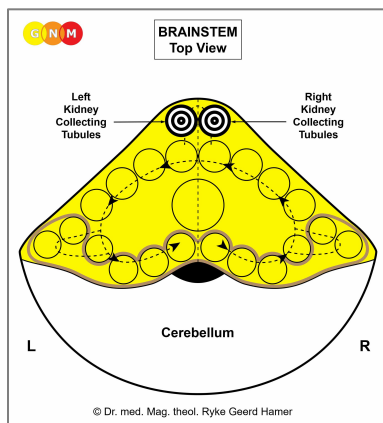
HEALING PHASE: During the healing phase the necrosis is reconstructed. The paralysis reaches into **PCL-A**. The Epileptoid Crisis presents as involuntary eye movement, called **nystagmus**. Depending on the exact nature of the conflict, the eyeball flutters up and down or side to side (compare with fluttering of the lens and pupil spasms). Recurring flutters are triggered by setting on a track that was established when the “don’t want to look there”-conflict took place. Uncontrollable eye movement could also occur together with a generalized seizure (grand mal) involving the entire **motor cortex**. After the Epileptoid Crisis, during **PCL-B**, the function of the eye muscle returns to normal.

At the end of the healing phase, the eye muscle will be stronger than before. This principle, namely that an organ works more efficiently after healing has been complete, applies without exception to all **cerebral medulla-controlled organs**.

Bulging eyes (proptosis, exophthalmos) is caused by an enlargement of structures within the eye socket pushing the globe of the eyes out of the orbit – like a telescope. Continuous swelling of the tear gland, for example, can lead to an anterior displacement of the eye. The same might occur with a buildup of connective tissue; in this case, the underlying conflict is a self-devaluation conflict. The condition, also known as **Graves’ disease or Basedow disease**, is generally associated with hyperthyroidism. From a GNM viewpoint, an overactive thyroid and a protrusion of the eyeball only occur together when the thyroid conflict is coupled with a self-devaluation conflict related to the eyes (“My eyes failed to be fast enough to catch or eliminate a morsel”).



The theory of a correlation between Graves’ disease and hyperthyroidism cannot explain why the eyeball protrusion affects only one eye. Based on the principle of laterality, a displacement of the left eye (as seen in this picture) reveals that the self-devaluation conflict is associated with the mother if the boy is right-handed.

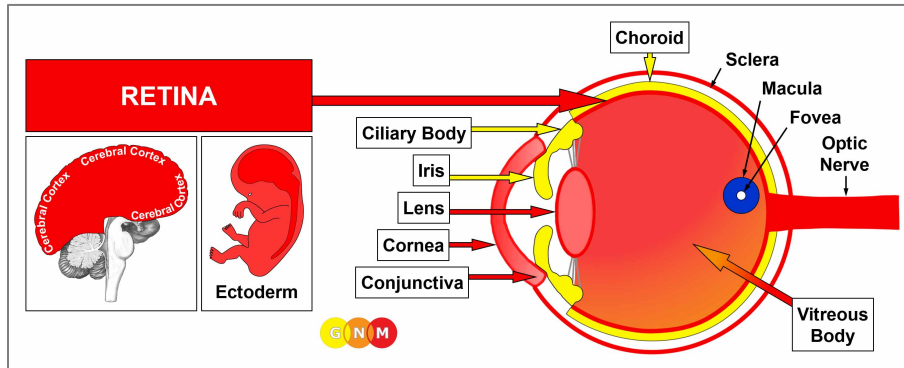


The **smooth lateral rectus** is supplied by the abducens nerve (sixth cranial nerve) that originates in the pons of the brainstem, precisely, in the control centers of the kidney collecting tubules.

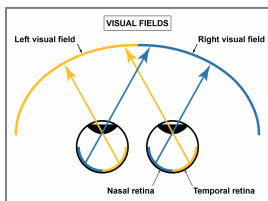
In the event of an abandonment or existence conflict, the lateral rectus pulls the eye(s) outward. When the conflict impacts in the right kidney tubules relay, the right eye deviates towards the right; when the left kidney tubules are affected, the left eye deviates towards the left. With two active abandonment or existence conflicts involving both kidney tubules, both eyes deviate sideways (see KCT Constellation). This is commonly called a “**lazy eye**”, or **amblyopia**. It should not come as a surprise that the condition often occurs in children. If the smooth part of the lateral rectus is affected, the person is able to pull the eye voluntarily into the correct position since the eye muscle is not paralyzed. In this case, the person is conflict active with an abandonment or existence conflict rather than with a visual “stuck”-conflict related to the **striated lateral rectus** with paralysis in the conflict-active phase (see strabismus exotropia).



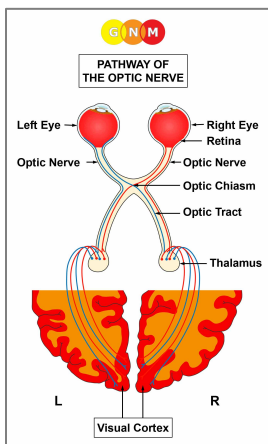
These two pictures of the French existentialist Jean-Paul Sartre show that at one time the right eye deviates outwards and another time the left eye, pointing to alternating existence conflicts.



DEVELOPMENT AND FUNCTION OF THE RETINA: The retina is a light-sensitive layer of nerves that lines the back of the eye. The retina contains neurons such as photoreceptors (rods and cones) that receive light and colors from the lens and convert them into impulses that are sent via the optic nerve to the visual cortex at the back of the brain. The **macula**, located near the central portion of the retina, is responsible for central vision. Within the central macula lies the fovea, which is a small pit that permits the highest visual acuity. The retina originates from the ectoderm and is controlled from the visual cortex.

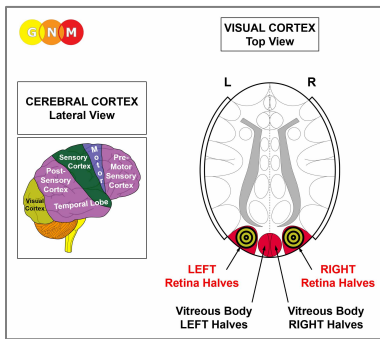


The **visual fields** of each eye are divided into a right and left field, called the temporal fields (close to the temporal bone) and nasal fields (close to the nose). Equally, the retina of each eye is divided into two halves: the temporal retina and the nasal retina. The right halves of the retina of both eyes (orange arrows) receive images predominantly from the left visual field (90% from the left, 10% from the right) whereas the left halves of the retina (blue arrows) receive images mainly from the right visual field (90% from the right, 10% from the left). Taking into account the refraction of light by the cornea and the lens, the image projected onto the retina is actually reversed. Therefore, what is in the temporal field of vision of either eye is perceived by the nasal retina and what is in the nasal field of vision is perceived by the temporal retina (see also vitreous body). **NOTE:** When the eyes were still positioned on the side, the visual fields did not overlap. The joint visual fields of both eyes developed after the eyes had moved to the front.



Pathway of the Optic Nerve: Visual perception, generated by photoreceptors in the retina, leaves the eyes by way of the optic nerve. The right and left branches of the optic nerve join behind the eyes, just in front of the pituitary gland, to form a cross-shaped structure called the **optic chiasma**. Within the optic chiasm, the nerve fibers from the nasal half of each retina cross over, but those from the temporal half do not since they are already positioned to see the reverse side of an image. After the optic chiasm, the nerves continue their path along the optic tracts. Most of the nerve fibers enter the thalamus. From there the nerves lead to the visual cortex at the back of the brain. The nerves of the right retina halves that receive images from the left visual field go to the right side of the visual cortex; the nerves of the left retina halves that receive images from the right visual field go to the left hemisphere. The crossing of the optic nerves at the chiasm is the requirement that the images projected onto the retina reach both sides of the visual cortex. There, the images seen by each eye are processed into a single picture, representing the image as it was originally perceived.

NOTE: The optic nerve emerged from the brain relays that innervated the primordial eyecup (today's choroid).



BRAIN LEVEL: The retina is controlled from the **visual cortex**. The right half of the retina of each eye is controlled from the right side of the visual cortex; the left half of the retina of each eye is controlled from the left brain hemisphere. There is no cross-over correlation from the brain to the organ.

NOTE: The control centers of the retina are next to the brain relays of the vitreous body.

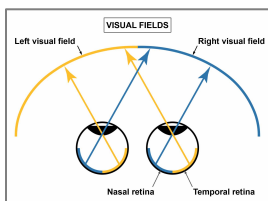
BIOLOGICAL CONFLICT: The biological conflict linked to the retina relates to a **fear that cannot be shaken off** (compare with vitreous body), for example, the fear of losing a loved one or one's home, the fear of punishment, abuse, unemployment (debts, poverty), persecution (religious, ethnic, political), or the fear of having cancer (medical tests, follow-up examinations). Children suffer the conflict when they witness domestic violence.

CONFLICT-ACTIVE PHASE: functional loss due to the loss of retinal photoreceptor cells with the **biological purpose** to make that what evokes the fear temporarily invisible (when children are scared, they cover their eyes). The loss of rod cells, responsible for vision at low light levels, results in **nyctalopia** or "night blindness" with difficulties seeing in dim light or in the dark.

NOTE: The retina belongs to the group of organs that respond to the related conflict not with cell proliferation or cell loss but with hyperfunction (see also periosteum and thalamus) or functional loss (see Biological Special Programs of the inner ear (cochlea and vestibular organ), olfactory nerves, vitreous body of the eyes, islet cells of the pancreas (alpha islet cells and beta islet cells), skeletal muscles).

Intense conflict activity leads to a **diminished vision in a defined area of the visual field (scotoma)** as a result of the breakdown of retinal cells (compare with scintillating scotoma). However, with a moderate conflict, the reduced vision might not be noticed since the other retina halves compensate the vision loss.

NOTE: Whether the right or left retina halves are affected is determined by a person's handedness and whether the conflict is mother/child or partner-related.



Concerning the retina, the principle of laterality is reversed (see also vitreous body).

The right halves of the retina (orange arrows) look predominantly to the left to receive images from the left visual field. Hence, for right-handed people the right retina halves relate to one's mother and child(ren), for left-handers to a partner.

The left halves of the retina (blue arrows) look to the right to receive images from the right visual field. Hence, for right-handed people the left retina halves relate to a partner, for left-handers to one's mother and child(ren).

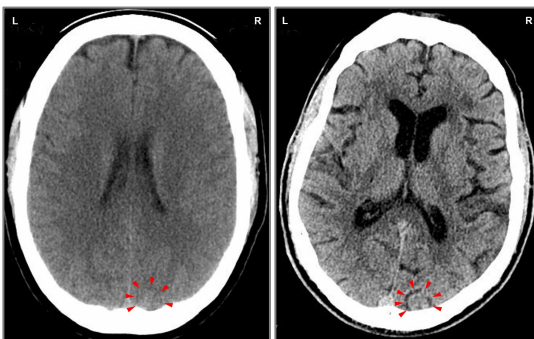
HEALING PHASE: During the healing phase the function of the photoreceptor cells is restored. In **PCL-A**, an edema forms between the choroid and the affected area of the retina. During the Epileptoid Crisis the edema is expelled, which is noticeable as **flashes of light** (photopsia). The flashes could be short bursts or happen continually until the retina is repaired.



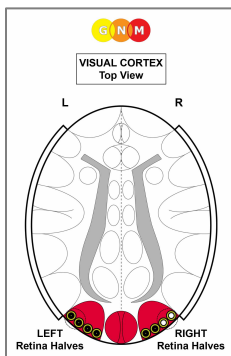
A “**scintillating scotoma**” presents as visual sparks, flickering lights, shimmering zig-zag lines, or colorful patterns in the visual field. Recurring episodes are triggered by setting on a track that was established when the original fear-conflict took place; their duration is determined by the intensity of the Epileptoid Crisis.

The visual auras often precede a migraine headache. However, not every person with a migraine headache experiences them and oftentimes the auras appear without the pain of migraines. Hence, we have to consider a combination of two different Epi-Crises events.

Recurring conflict relapses lead to the buildup of scar tissue and a hardening (callosity) in the retina. If the hardening occurs laterally (on the side), the **eyeball elongates** causing **nearsightedness** or **myopia** (see also smooth ciliary muscle and cornea), whereas hardening in the back (dorsal) **compresses the eyeball** causing **farsightedness** or **hyperopia** (see also lens and striated ciliary muscle in both eyes). At this point the condition is irreversible.




Both CT scans show a Hamer Focus (on different layers) in the right retina relay for the right retina halves of both eyes. The image on the left presents the conflict-active phase (sharp ring configuration); the image on the right the healing phase (edematous ring). For a right-handed person the fear-conflict relates to his/her mother or children; for a left-handed person to a partner (see handedness above).



NOTE: The right retina halves look 90% to the left and 10% to the right (the left retina halves look 90% to the right and 10% to the left) – see visual fields. If the impact of the retina-related conflict occurs in the outer portions of the right retina relay (see GNM diagram) only the right eye is affected (the same applies to the vitreous body).

A large edema between the choroid and retinal layer (usually because of water retention due to the SYNDROME) pulls the retina from its normal position. This is generally called a **retinal detachment** (strictly speaking, a misnomer since the retina does not “detach”). With no conflict relapses the condition reverses on its own. However, if the fear-conflict persists healing cannot be complete and the vision becomes drastically reduced. The panic of becoming blind often adds new fears creating a progressive condition. **CAUTION:** Stooping or physical exertion, for example when lifting something heavy, can cause a rupture of the retina!



The edema that develops between the choroid and the retina (in **PCL-A**) causes a loss of peripheral vision (see also vitreous body).

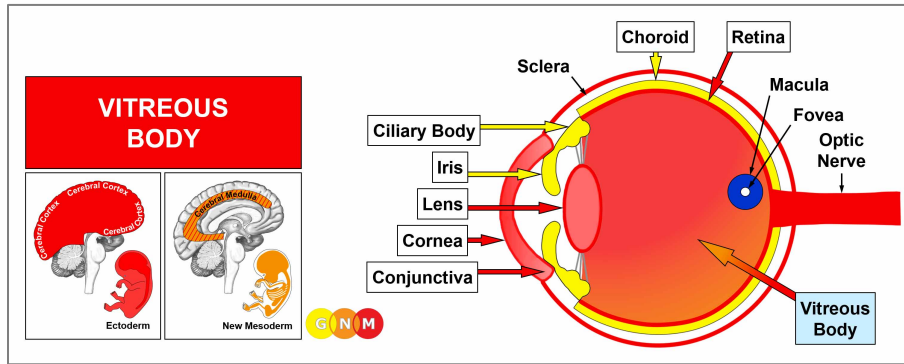
When the left retina halves are affected, as seen in this image, the fear-conflict is associated with a partner, if the person is right-handed; for a left-hander with his/her mother or children (see handedness above).

What is termed “**diabetic retinopathy**” is based on the assumption that an elevated blood sugar level damages the retina. Yet, not every diabetic develops the condition! From the GNM point of view, it is the additional resistance conflict (a resistance to the fear-provoking situation) why the two Biological Special Programs often run simultaneously (see also “diabetic peripheral neuropathy” related to the periosteum).

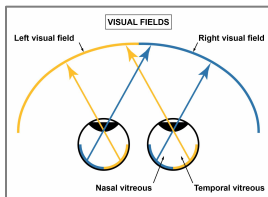


A **loss of central vision** develops when the healing process involves the macula, a small and highly sensitive part of the retina responsible for detailed central vision (compare with the loss of peripheral vision related to the vitreous body).

A “**dry macular degeneration**” occurs, in GNM terms, in the conflict-active phase; a “**wet macular degeneration**”, indicating the presence of an edema (fluid accumulation), during the healing phase. A common symptom of a **macula edema** is a **blurred, central vision** (compare with blurry vision related to the cornea). If healing cannot be complete because of continuous conflict relapses, the condition can lead to blindness.

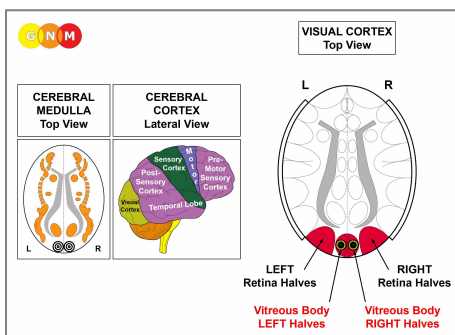


DEVELOPMENT AND FUNCTION OF THE VITREOUS BODY: The vitreous body occupies the space between the lens and the retina at the back of the eye. Fluid produced in the ciliary body fills the vitreous with a gel-like substance made up of about 99% water. The gel, composed mainly of collagen, is transparent so that light rays are able to pass through it to reach the retina. The intraocular pressure maintains the shape of the eye and prevents the walls of the eyeball from collapsing. The sclera, a sheath of connective tissue, supports the eyeball from the outside. The vitreous body consists of mesodermal parts, controlled from the cerebral medulla, and ectodermal parts, controlled from the visual cortex.



Like the retina, the vitreous body is divided into two halves, a temporal vitreous (close to the temporal bone) and a nasal vitreous (close to the nose). This confirms that the vitreous body and the retina are functionally closely connected.

Analogous with the information transfer of the right and left retina halves, the images perceived from the right and left visual field go from the right and left halves of the vitreous body over the optic chiasm to the visual cortex (see pathway of the optic nerve).



BRAIN LEVEL: The control centers of the vitreous body are in the **visual cortex** (ectodermal parts) and in the **cerebral medulla** (mesodermal part). The right half of the vitreous of each eye is controlled from the right side of the cerebrum; the left halves of the vitreous of each eye are controlled from the left cerebral hemisphere. There is no cross-over correlation from the brain to the organ.

NOTE: The control centers of the vitreous body are next to the brain relays of the retina.

BIOLOGICAL CONFLICT: The biological conflict linked to the vitreous body is a **fear of a “predator”** who is “sneaking up from behind” (compare with a “fear that cannot be shaken off” related to the retina). Thus, the conflict is always a fear of a person, for example, the fear of an abuser, a stalker, a character assassin, a threatening ex-spouse, a relative who is after one’s inheritance, a supervisor, a teacher, a parent, a doctor, a lawyer, or an authority (government, tax office, bailiff, police, judge) that is “breathing down one’s neck”. The fear could also be experienced as feeling pressured by someone to perform (at school, at home, at work).

NOTE: Whether the right or left halves of the vitreous body are affected is determined by a person’s handedness and whether the conflict is mother/child or partner-related. As with the retina, **the principle of laterality is reversed**. Hence, for a right-handed person the right halves of the vitreous relate to his/her mother and child(ren), the left halves of the vitreous body to a partner; for left-handed people it is the other way around.

CONFLICT-ACTIVE PHASE: **necrosis** (controlled from the cerebral medulla) and **functional loss** of the vitreous body (controlled from the visual cortex), causing an interference of the transmission of light to the retina and consequently a **clouding of the vitreous** (compare with clouding of the lens). Considering that due to the refraction of light by the cornea and the lens the images projected onto the retina are reversed (what is perceived in the temporal field of vision is registered on the nasal vitreous), the clouding of the vitreous **affects predominantly the nasal halves and therefore the peripheral vision** (see visual fields). The **biological purpose of the clouding** is to blur the sight of the “predator” (horse-blinkers phenomenon) to be able to focus fully on the escape route.

NOTE: The vitreous body belongs to the group of organs that respond to the related conflict not with cell proliferation or cell loss but with hyperfunction (see also periosteum and thalamus) or functional loss (see Biological Special Programs of the inner ear (cochlea and vestibular organ), olfactory nerves, retina of the eyes, islet cells of the pancreas (alpha islet cells and beta islet cells), skeletal muscles).

HEALING PHASE: During the healing phase the clouding of the vitreous body recedes. In **PCL-A**, an edema (fluid accumulation) develops at the site, which increases the intraocular pressure in the eye. With the SYNDROME, that is, with water retention as a result of an active abandonment or existence conflict, the eye pressure rises even more. During the Epileptoid Crisis the edema is pressed out. However, in order to keep the eyeball firm and prevent it from collapsing, the **intraocular pressure remains elevated during and shortly after the Epileptoid Crisis** (in **PCL-B**). With a hanging healing due to continuous conflict relapses the optic nerve becomes damaged, particularly when the edema reaches into the opening of the vitreous where the optic nerve leaves the eye. In conventional medicine, damage to the optic nerve is called a **glaucoma** or “**green cataract**” (compare with “grey cataract” related to the lens).



Recurring Epi-Crisis episodes (“glaucoma attacks”) lead to a progressive **loss of peripheral vision**, also known as **tunnel vision** (compare with the loss of central vision related to the macula), and eventually to blindness.

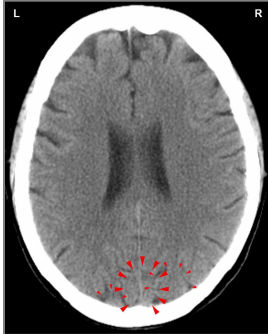NOTE: The **ciliary body** produces a watery fluid that fills the **anterior and posterior eye chamber** to maintain the intraocular pressure of the eye. Parts of the fluid are released into the vitreous body. If too much fluid is produced, caused by the **cell proliferation** in the ciliary body due to an active “visual morsel” conflict, the additional fluid leaks into the vitreous. With lasting conflict activity, the **increased intraocular pressure** damages the optic nerve. In conventional medicine, this is called a “secondary glaucoma”. In this case, the glaucoma occurs in the **conflict-active phase** and is related to the ciliary body!

The optic nerve is supplied by **blood vessels**, linked to an eye-related self-devaluation conflict. During the healing process (**PCL-B**), the inner wall of the blood vessel might tear and bleed. The SYNDROME increases the risk of a tear significantly. In this case, the optic nerve gets damaged even though the **intraocular pressure is within the normal range**. In conventional medicine this is called a “normal-tension glaucoma”.

The **trabecular meshwork**, located near the ciliary body, is responsible for the outflow of intraocular fluid. It consists mainly of connective tissue, related to a self-devaluation conflict associated with the eye(s). During the healing phase (**PCL-B**), when the **cell loss** is replenished through cell proliferation, the fluid outflow could get blocked. **The backup of fluid increases the intraocular pressure**, which in turn damages the optic nerve. In conventional medicine this is called an “open-angle glaucoma”.

Permanent elevated eye pressure causes a depression of the optic disc, termed **excavation papillae** (compare with papilledema, a swelling of the optic nerve due to increased intracranial pressure; see hydrocephalus).

The scarring process (**PCL-B**) in the vitreous body is noticeable as **eye floaters** (mouches volantes) that appear as spots, threads, black or grey specks, strings or cobwebs that drift about with the movement of the eyes. Floaters are visible because of the shadows they cast on the retina. After the healing process has been completed, the floaters disappear. With a hanging healing the vitreous body slowly shrinks and pulls away from the retina. This is called a **vitreous detachment**. What is known as a “Weiss ring” is a circle-shaped floater that is created by a *posterior* vitreous detachment around the optic nerve in the back of the eye (compare with retinal detachment). The separation from the retina causes damage to the retina’s surface. When this occurs, the retina initiates a healing process and forms scar tissue, or an epiretinal membrane. If the scar tissue forms over the macula, the part of the eye responsible for central vision, this is called a **macular pucker**, as it causes the macula to “pucker” or wrinkle as it shrinks (compare with macular degeneration).



This CT scan shows a central conflict (related to a person’s mother/child and partner) in the area of the visual cortex that controls the vitreous body ([view the GNM diagram](#)). The small arrows point to the control centers of the retina ([view the GNM diagram](#)) with a Hamer Focus in both brain hemispheres. The partly edematous rings (**PCL-A**) indicates that the person has still relapses of fear conflicts. The combination of the Biological Special Programs of the retina and vitreous body occurs, for example, if a child lives in fear of being punished (retina) by its parents (vitreous body).

Source: www.learninggnm.com